

Promotive Effects of a Silk Film on Epidermal Recovery from Full-Thickness Skin Wounds (44552)

AKIRA SUGIHARA,*† KIKUYA SUGIURA,* HARUO MORITA,* TAKASHI NINAGAWA,‡ KOUZOU TUBOUCHI,§ RYUUKICHI TOBE,¶ MAMORU IZUMIYA,# TAKESHI HORIO,† NADER G. ABRAHAM,**¹ AND SUSUMU IKEHARA*¹

**The First Department of Pathology and †Department of Dermatology, Kansai Medical University, Osaka, Japan; ‡Silk Kogei Co., Ltd., Kyoto, Japan; §National Institute of Sericultural and Entomological Science, Ministry of Agriculture, Forestry and Fisheries, Tukuba, Japan; ¶Hamamatsu Rosai Hospital, Hamamatsu, Japan; #Izumiya Hospital, Kyoto, Japan; and **Department of Pharmacology Gene Therapy Laboratories, New York Medical College, Valhalla, New York 10595*

Abstract. We examined the effects of the transparent fibroin film (silk film) on full-thickness skin wounds. Full-thickness dermatotomies (15 mm × 9 mm) were prepared on the dorsal wall of CRJ:CD-1 *nu/nu* (ICR *nu/nu*) mice. The area of the wounds dressed with silk film was reduced to 10% of that made by the dermatotomy 14 days after the dermatotomy and were covered with regenerated epidermis 21 days after the dermatotomy. In contrast, less recovery and epidermal regeneration were found 14 days after dermatotomy in the wounds dressed with a conventional hydrocolloid dressing (Duro Active). Furthermore, only partial incomplete epidermal growth was obtained 21 days after dermatotomy. Most importantly, the healing time of wounds dressed with silk film was 7 days shorter than those dressed with DuoActive dressing. The silk film showed an almost similar or slightly better promotive effect as the lyophilized porcine dermis (Alloask D), which is used as a dressing for burns, ulcers, and decubitis. Histologic findings revealed that there was greater collagen regeneration and less inflammation and neutrophil-lymphocyte infiltration of the wounds dressed with silk film than with DuoActive dressing. It is clear that regeneration of the epidermis and dermis of the wound beds covered with silk film was faster than with DuoActive dressing. Finally, silk film is easily obtainable, sterilizable, and transparent, and it allows easy observation of tissue recovery. Therefore, silk film offers advantages over other dressings and may be clinically useful for wound treatment.

[P.S.E.B.M. 2000, Vol 225:58–64]

Accidental removal or damage to the epidermis by ulcers, burns, or other traumatic experiences may result in a series of morbid consequences that restrict epidermal regeneration. In this respect, dehydration, ionic imbalances, necrosis, and infection may lead to severe trauma, shock, and even death. Therefore, it is essential to

apply an adequate dressing to permit maximal recovery of the dermis and epidermis.

To promote healing, wound dressings should have the following functions: (i) draining of exudate; (ii) prevention of evaporative water loss; (iii) control of insensible perspiration from wound surface; and (iv) prevention of bacterial infection. Furthermore, wound dressings should reduce pain and discomfort. To satisfy these conditions, wound dressings are required to be homogeneous membranes and have structures that allow them to adhere to the whole wound surface. Homografts are useful for temporary resurfacing of wounds, but it is often difficult to obtain an adequate supply of suitable tissues, and homografts cannot be used for repeated grafts for rejections. Moreover, there is a risk of infecting the donors with several pathogens such as HIV (1).

Since the 1960s many new wound dressings have been developed. Wound dressings have been classified into three

¹ To whom requests for reprints should be addressed at the First Department of Pathology, Kansai Medical University, 10-15 Fumizono cho, Moriguchi City, Osaka 570–8506, Japan. E-mail: ikehara@takii.kmu.ac.jp

Received December 16, 1999. [P.S.E.B.M. 2000, Vol 225]
Accepted April 26, 2000.

0037-9727/00/2251-0058\$15.00/0
Copyright © 2000 by the Society for Experimental Biology and Medicine

groups: biological dressings, synthetic dressings such as formal polyvinyl alcohol sponge, and synthetic composite dressings such as collagen sponge. Biological dressings include untreated biological materials and chemically treated ones. Sterilized lyophilized porcine skin and dermis (2–5), collagen membrane prepared from biomaterials (6, 7), calcium sodium alginate from seaweeds (8, 9), and the recently developed collagen-alginate dressing (10, 11) have been developed as biological dressings. A polyethylene film has also been found to provide good connective tissue regeneration and tissue growth (12). Alloask D is an example of the lyophilized porcine dermis, and DuoActive is another example of a wound dressing made of hydrocolloid.

In wound treatment, open therapy was generally carried out until the 1960s. However, since the 1970s, the concept of moist wound healing using occlusive wound dressings has become the norm. Experimental results have shown that wounds grow epithelium more rapidly under moist conditions than under dry. Wound dressings keep wounds moist and promote growth of granulation tissue, and the epidermization decreases pain and reduces scar formation. Furthermore, wound dressings possibly concentrate growth factors and cytokines in the wound area, which may be necessary for adequate tissue regeneration.

Fibroin is a silk protein and comprises the core of silk fiber. Recently, fibroin has gained attention as a new biological material, and there have been several studies on the biological functions of fibroin. Fibroin appears to have minimal adverse effects on the immune system and inhibits increases in cholesterol levels in the peripheral blood (13). Since fibroin is highly hydrophobic, this protein may be a material that can be used for wound dressings and provide the necessary requirements for recovery. It is also easy to obtain as a sterile dressing. In this study, to examine whether fibroin is applicable as a biological dressing, we prepared silk film from fibroin and compared the function of silk film with two clinically used dressings, hydrocolloid dressing and lyophilized porcine dermis, in the healing of murine full-thickness skin wounds.

Materials and Methods

Dressings. Silk film (thickness 0.3 mm) is composed of a protein of silk fiber, fibroin, and is made by dissolution of refined silk fiber in a potassium chloride solution following deionization. DuoActive dressing (a hydrocolloid dressing) (14–17) was purchased from Bristol-Myers Squibb Co. (Tokyo, Japan). Alloask D (lyophilized irradiated porcine dermis) was purchased from Taiho Pharmaceutical Co. (Tokushima, Japan) (2–5).

Full-Thickness Skin Wound Preparation. Male CRJ:CD-1 *nu/nu* (ICR*nu/nu*) mice were purchased from Charles River Japan (Yokohama, Japan), and used at 7–8 weeks old. For the three experimental groups and controls, 150 mice were used. Full-thickness dermatotomies (15 mm × 9 mm) were prepared on the dorsal wall of the mice (Figs. 1A & 1B). These wounds were covered with the silk film,

DuoActive dressing, and Alloask D. Alloask D was macerated with sterile saline before use. These wounds were then covered with sterilized gauze and fixed with elastic bandage. All mice were given tetracycline (2 mg/ml) in acidified drinking water (pH 2.7). Three or more mice in each group were sacrificed, and macroscopic and histologic inspections of the skin wound were carried out once a week. As the wound was almost square, unepithelized areas were calculated from the length and width of the wound. After measurement of the wound areas, wounds together with surrounding tissues were excised and fixed with 3% formaldehyde. Sections of the wound tissues were stained with hematoxylin and eosin (H&E) for the histologic inspection.

Collagen Determination. The presence of collagen was determined by the light microscopy of skin wound histologic preparations stained with H&E and differential verification with aniline blue. The fibers appeared as wavy structures of variable width and intermediate length. Their presence was scored as mild (+), moderate (+ +), or normal (+ + +), and relative absence (–).

Evaluation of Inflammatory Cells. Random sample areas of the wounds were examined by light microscopy and inflammatory cells (polymorphonuclear leukocytes (PMN-) and lymphocytes) were identified according to the morphological criteria. Their presence was scored as few (+), moderate (+ +), and many/considerable (+ + +, + + + +).

Epidermal Assessment. Histologic preparations were examined for the extent of epidermal growth. The epidermis could easily be distinguished from the dermis on the basis of standard histologic criteria such as the basement membrane and developing keratinocytes, whereas the dermis has much collagen and inflammatory cells present.

Results

Appearance of the Wound Surfaces Treated with Three Dressings. Seven days after the dermatotomy, unepithelized areas of the wound dressed with silk film had decreased to about 46% of the area made by dermatotomy. The wound surface dressed with silk film showed suitable moisture and was covered with a thin crust surrounded by brownish red granulation. In some cases, the wound had shrunk, and epithelization was found at the edge of the wound (Fig. 1A). In contrast, 97% of the areas dressed with DuoActive dressing remained unepithelized. The wound surface dressed with DuoActive dressing showed ulceration surrounded by a thick crust. The amount of hydrocolloid gel slightly decreased by dissolution in exudate (Fig. 1B). Unepithelized areas of the wound dressed with Alloask D had also decreased to 46%. The wound surface dressed with Alloask D had almost the same appearance as that dressed with silk film.

Fourteen days after dermatotomy, the unepithelized areas of the wound dressed with silk film had decreased to 7%. The wound dressed with silk film had shrunk significantly. Most of the wound surface was covered with epi-

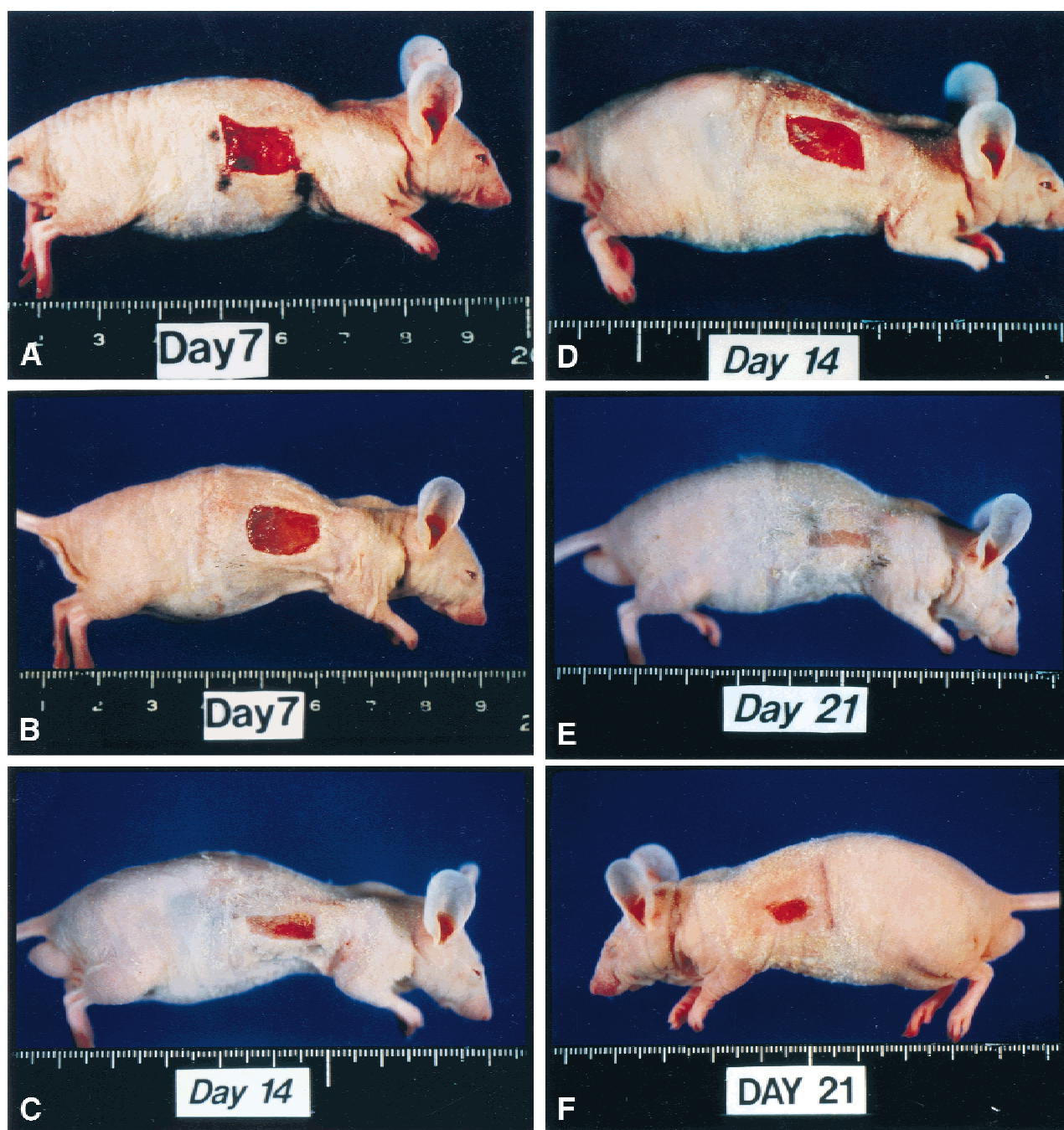


Figure 1. Change in appearance of wounds dressed with silk film and DuoActive dressing after full thickness dermatotomy. (A) Appearance of silk film-dressed wound on Day 7 after dermatotomy. (B) Appearance of the DuoActive dressing-dressed wound on Day 7 after dermatotomy. (C) Appearance of the silk film-dressed wound on Day 14 after dermatotomy. (D) Appearance of the DuoActive dressing-dressed wound on Day 14 after dermatotomy. (E) Appearance of the silk film-dressed wound on Day 21 after dermatotomy. (F) Appearance of the DuoActive dressing-dressed wound on Day 21 after dermatotomy.

thelial cells (Fig. 1C). Unepithelized areas of the wound dressed with DuoActive dressing had decreased to about 56%, and epithelization had begun from the rim of the normal skin (Fig. 1D). The area and surface of the wound dressed with Alloask D were almost the same as that with silk film; unepithelized areas were at least 9% of the dermatotomy area.

Twenty-one days after dermatotomy, the wounds dressed with silk film and Alloask D had almost completely

epithelized (Fig. 1E). The wound dressed with the DuoActive dressing had significantly shrunk, and remarkable epithelization was noted. However, at least 7% of the areas dressed with DuoActive dressing remained unepithelized, and the granulation tissue covered with crust was still there (Fig. 1F).

The changes of the unepithelized areas described above are summarized in Table I and Figure 2. In contrast to the DuoActive dressing, note that the wounds exposed to silk

Table I. Percentage Changes in Unepithelized Areas Dressed with Silk Film, DuoActive, and Alloask D

Days after dermatotomy	% Unepithelized area		
	7	14	21
Dressing			
Silk Film	46	7	0
DuoActive	97	56	7
Alloask D	46	9	0

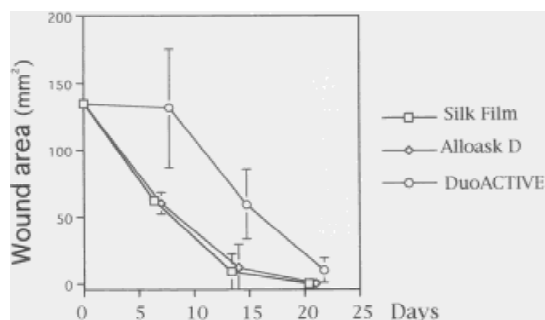


Figure 2. Comparison of changes in unepithelialized area dressed with silk film, DuoActive dressing, and Alloask D. The wound dressed with silk film healed 7 days faster than that dressed with DuoActive dressing. The silk film demonstrated a similar promotive affect on healing as Alloask D. In the silk film-dressed group, four mice were sacrificed on Day 7; four mice on Day 14; and four mice on Day 21. In the DuoActive dressing-dressed group, four mice were sacrificed on Day 7; five mice on Day 14; and four mice one Day 21. In the Alloask D dressing-dressed group, three mice were sacrificed on Day 7; four mice on Day 14, and four mice on Day 21.

film and Alloask D recovered at the same rate and extent. In Table I it can be seen that the recovery of epithelization (given as percentage of unepithelization) for silk film and Alloask D was similar at 7, 14, and 21 days, respectively. Note that on Day 14, silk film and Alloask D had only 7% and 9% unepithelized areas, respectively, whereas they had both completely healed by Day 21. Figure 2 shows the actual changes in the measured wound area (mm^2) of the three groups.

Histologic Findings of Wounds Dressed with Three Dressings. Seven days after dermatotomy, the wounds dressed with the DuoActive dressing were severely edematous and covered with a thick crust. Severe infiltration of neutrophils and lymphocytes was observed in the subcutis of the wound. The formation of granulation tissue was observed at the rim of the intact skin tissue; however, epidermization was not observed (Fig. 3A). In contrast, there was significantly less edema in the wounds dressed with the silk film than those dressed with the DuoActive dressing. Infiltration of neutrophils in the subcutis was also very slight. Epidermization and granulation tissue were observed at the edge of the intact skin tissue (Fig. 3D). The wounds dressed with Alloask D showed almost the same result as with silk film, except that the wounds dressed with Alloask D showed more infiltration of neutrophils (not shown).

Fourteen days after dermatotomy, although small epidermal defects remained, epithelial cells had grown over the surface of the wound dressed with silk film. In the tissue under the wound, edema further decreased, and the granulation tissue was replaced by collagen fibers. Infiltration of a few lymphocytes was observed (Fig. 3E). In contrast, the wounds dressed with DuoActive dressing were still edematous, inflammatory granulation tissue had grown to cover the surface of the subcutis, and no epidermization was yet observed (Fig. 3B). The wounds dressed with Alloask D were similar to the wounds dressed with silk film. They showed epidermization, a decrease in the number of inflammatory cells, a reduction of edema, and replacement of granulation tissue by collagen fibers.

Twenty-one days after dermatotomy, in the areas dressed with the silk film or Alloask D, regenerated epidermis covered the wound surface completely. Most of the granulation tissue had been replaced by collagen fiber. The inflammatory cells had disappeared (Fig. 3F). In the wounds dressed with DuoActive dressing, the growth of epithelial cells from around the skin tissue was observed, and collagen fiber had started to replace the granulation tissue. Inflammatory cells had decreased, but necrotic tissue remained across most of the unepithelized area (Fig. 3C). The above results are presented in Table II and diagrammatically summarized in Figure 4.

In summary, the wound dressed with silk film showed epithelization 7 days before that dressed with the DuoActive dressing. The silk film demonstrated similar promotive effects on epithelization as Alloask D.

Discussion

In the past several years, occlusive wound dressings, which keep wounds moist, have become the norm in the treatment of skin defects caused by ulcers, decubitis, abrasions, and skin graft rejection (18–22). Many new wound dressings have been designed to keep the wound moist while it heals. In this report, we have examined and compared the effects of silk film, DuoActive, and Alloask D on the healing of full-thickness skin defects caused by dermatotomy. As indicated, silk film was developed as a new biological dressing from fibroin, a silk protein. Results show that wounds dressed with silk film healed 7 days faster than those dressed with DuoActive dressing, and the silk film demonstrated the same or better promotive effects on healing as the lyophilized porcine dermis, Alloask D. These results suggest that silk film as a wound dressing would be useful in the clinical treatment of skin defects, providing that infection or growth of bacteria on the wound surface is prevented by a combination of antibiotics. Furthermore, because silk film is transparent, the wound is easily observed through it.

As indicated, synthetic and biological dressings must drain exudate, diminish evaporative water loss from the wound surface, and promote epithelization (23). In this study, microscopic analyses revealed that the tissues under

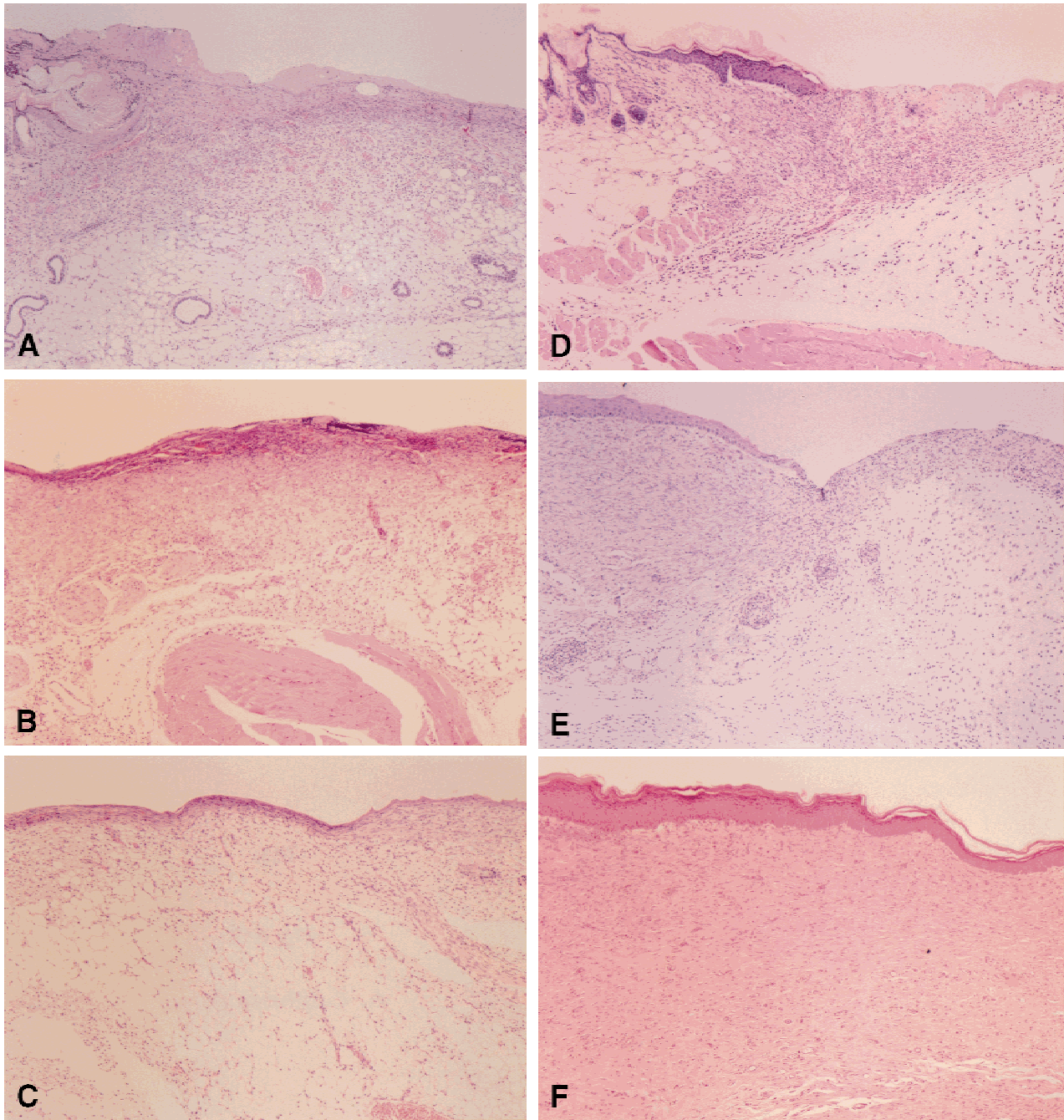


Figure 3. Histologic findings of wounds dressed with silk film and DuoActive dressing after dermatotomy. (A) Histologic findings of DuoActive dressing-dressed wounds on Day 7 after dermatotomy. The rim of the wound is shown. Epithelialization from the rim of the wound is not found. Granulation tissue with edema and significant infiltration of neutrophils and lymphocytes are present. H&E, $\times 40$. (B) Histologic findings of DuoActive dressing-dressed wounds on Day 14 after dermatotomy. Epithelialization is beginning from the rim of the wounds. However, moderate infiltration and edema still remain in the unepithelialized center of the wounds. The figure shows unepithelialized center (granulation tissue) of wounds. H&E, $\times 40$. (C) Histologic findings of DuoActive dressing-dressed wounds on Day 21 after dermatotomy. Significant epithelialization is found. However, in the center of the wounds, necrotic tissue and granulation tissue with moderate infiltration remain. H&E, $\times 40$. (D) Histologic findings of silk film-dressed wounds on Day 7 after dermatotomy. Compared with the wound dressed with DuoActive dressing, slight epithelialization and less infiltration and edema are found. H&E, $\times 40$. (E) Histologic findings of silk film-dressed wounds on Day 14 after dermatotomy. The rim of the wound is shown. Significant epithelialization is found. In the granulation tissues under epithelialization, there were fewer infiltrated cells and edema was reduced. H&E, $\times 40$. (F) Histologic findings of silk film-dressed wounds on Day 21 after dermatotomy. Whole wound surface is covered with regenerated epithelial cells. The granulation tissue under the regenerated epidermis has been replaced with collagen fiber, and infiltrated inflammatory cells almost disappear. H&E, $\times 40$.

the wound dressed with the DuoActive dressing were highly edematous, whereas those dressed with silk film were in the early stages of healing. This difference suggests that the silk

film has a better capacity to drain exudate from wounds than the DuoActive dressing. Edema, caused by the retention of exudate, induces disorders in the bloodstream and the mi-

Table II. Histological Changes in Dressed Wounds at 7, 14, and 21 Days After Dermatotomy

Dressing/days	Histological criteria			
	Edema	Crust	Neutrophil/lymphocyte infiltration	Collagen/granulation
Silk film				
7	++	++	++	+
14	+	+	+	+
21	–	–	–+++	collagen
DuoActive				
7	++++	+++	++++	±
14	+++	++	+++	+
21	±	+	++	+collagen/necrosis
Alloask D				
7	++	++	++	+
14	+	+	+	+
21	–	–	–	++collagen




Figure 4. The comparison of histologic changes in wounds dressed with silk film and DuoActive. Figures represent relative percentage versus time after dermatotomy.

gration of neutrophils, which, in turn, may delay wound healing (23). In addition, when we observed wounds dressed with silk film once a week, the wounds appeared to be kept suitably moist. Based on this finding, we believe that silk film has the ability to retain water, proteins, and electrolytes, although we have no direct evidence. This retention may keep the concentrations of important substances such as transforming growth factor (TGF)- α , TGF- β , interleukin (IL)- α , IL- β , IL-6, keratinocyte growth factor, and other cytokines in the granulation tissue at adequate levels (24–28). These cytokines promote the growth of keratinocytes, fibroblasts, and angioendothelial cells. Indeed,

faster epithelization and granulation were observed in the wounds dressed with silk film than those dressed with the DuoActive dressing.

In addition to silk film, we examined the effect of fibroin powder (the silk powder) on the healing of full-thickness skin defects. It was found that the healing (complete regeneration of epithelial cells) of wounds dressed with the silk powder was faster than the wounds dressed with DuoActive dressing, but slower than the silk film. Since silk powder has spaces between the particles, excessive exudate may be retained in the spaces rather than evaporate. The over-retention of water may inhibit the drainage of exudate newly produced from the wound surface.

The biological implications of our observations with the use of silk film as a dressing are many. It can (i) be obtained easily, (ii) be sterilized, (iii) allow observations on wound healing, (iv) support collagen synthesis, (v) reduce edema and scarring due to inflammatory responses, and (vi) promote epithelization. Indeed, a readily obtainable dressing such as silk film may have applications for emergency situations such as severe burns where hospitalization is not immediately available.

Studies are underway to analyze the direct effect of fibroin on the growth of keratinocytes and fibroblasts and on the production and significance of growth-promoting cytokines by macrophages *in vitro*. Results from these studies may provide insight into ways to provide or apply cytokines as therapeutic agents in wound recovery with dressings.

- Gallico GG III. Biologic skin substitutes. *Clin Plast Surg* **17**:519–526, 1990.
- Bromberg BE, Song IC, Mohn MP. The use of pig skin as a temporary biological dressing. *Plast Reconstr Surg* **36**:80–90, 1965.
- Hackett M, Bowen J. Preliminary report on the comparative use of lyophilized homograft and xenograft in the closure of raw areas. *Br J Surg* **61**:427–429, 1974.
- Rundle JS, Cameron SH, Ruckley CV. New porcine dermis dressing for varicose and traumatic leg ulcers. *Br Med J* **24**:216, 1976.
- Nakano S, Kuwata M, Morita K. Effect of lyophilized dermis porcine skin on experimental skin wound. *Ouyou Yakuri* **23**:121–140, 1982.
- Yang JY. Clinical application of collagen sheet, YCML, as a burn wound dressing. *Burns* **16**:457–461, 1990.
- Sakiel S, Grzybowski J. Clinical application of new bovine collagen membranes as a partial-thickness burn wound dressing. *Polimers Med* **25**:19–24, 1995.
- Attwood AI. Calcium alginate dressing accelerates split skin graft donor site healing. *Br J Plast Surg* **42**:373–379, 1989.
- Vanstraelen P. Comparison of calcium sodium alginate (KALTO-STAT) and porcine xenograft (E-Z DERM) in the healing of split-thickness skin graft donor sites. *Burns* **18**:145–148, 1992.
- Donaghue VM, Chrzan JS, Rosenblum BI, Giurini JM, Habershaw GM, Veves A. Evaluation of a collagen-alginate wound dressing in the management of diabetic foot ulcers. *Adv Wound Care* **11**:114–119, 1998.
- Van Gils CC, Roeder B, Chesler SM, Mason S. Improved healing with a collagen-alginate dressing in the chemical matricectomy. *J Am Podiatr Med Assoc* **88**:452–456, 1998.
- Linsky CB, Rovee DT, Dow T. Effects of dressings on wound inflam-

- mation and scar tissue. In: Dineen P, Hildick-Smith G, Eds. *The Surgical Wound*. Philadelphia: Lea & Febiger, pp191–205, 1981.
13. Chen K, Iura K, Takano R, Hirabayashi KA. Effect of fibroin administration on the blood cholesterol level of rats loaded with cholesterol. *J Sericultural Sci Japan* **62**:56–60, 1993.
 14. Alvarez OM, Mertz PM, Eaglstein WH. The effect of occlusive dressings on collagen synthesis and re-epithelialization in superficial wounds. *J Surg Res* **35**:142–148, 1983.
 15. Yarkony GM, Kramer E, King R, Lukanc C, Carle TV. Pressure sore management: Efficacy of a moisture reactive occlusive dressing. *Arch Phys Med Rehabil* **65**:597–600, 1984.
 16. Friedman SJ, Su WP. Management of leg ulcers with hydrocolloid occlusive dressing. *Arch Dermatol* **120**:1329–1336, 1984.
 17. Biltz H, Kiessing M, Kreysel HW. Comparison of hydrocolloid dressing and saline gauze in the treatment of skin graft donor sites. In: Ryan TJ, Ed. *An Environment for Healing: The Role of Occlusion*. London: The Royal Society of Medicine, Session 5:pp125–128, 1985.
 18. Falanga V. Occlusive wound dressing, why, when, which? *Arch Dermatol* **124**:872–877, 1988.
 19. Hermans MHE. Wound management with occlusive materials: A review. *J Jpn Plast Reconstr Surg* **12**:465–473, 1992.
 20. Waffle C, Simon RR, Joslin C. Moisture-vapor-permeable film as an outpatient burn dressing. *Burns Incl Therm Inj* **14**:66–70, 1988.
 21. Young SR, Dyson M, Hickman R, Lang S, Osborn C. Comparison of the effect of semi-occlusive polyurethane dressings and hydrocolloid dressings on dermal repair: 1. Cellular changes. *J Inv Dermatol* **97**:586–592, 1991.
 22. Brown AS, Barot LR. Biologic Dressings and skin substitutes. *Clin Plast Surg* **13**:69, 1986.
 23. Castor CW. Tissue repair and regeneration. *Handbook of Inflammation* (3rd ed). North Holland: Elsevier, p177, 1981.
 24. Finch PW, Rubin JS, Miki T, Ron D, Aaronson SA. Human KGF is FGF-related with properties of a paracrine effector of epithelial cell growth. *Science* **245**:752–755, 1989.
 25. Ono I, Gunji H, Suda K, Iwatsuki K, Kaneko F. Evaluation of cytokines in donor site wound fluids. *Scand J Plast Reconstr Surg Hand Surg* **28**:269–273, 1994.
 26. Ono I, Gunji H, Zhang JZ, Maruyama K, Kaneko F. Studies on cytokines related to wound healing in donor site wound fluid. *J Dermatol Sci* **10**:241–245, 1995.
 27. Buchan IA, Andrews JK, Lang SM. Laboratory investigation of the composition and properties of pig skin wound exudate under Op-site. *Burns* **8**:39–46, 1982.
 28. Abbas AK, Lichtman AH, Pover JS. *Cellular and Molecular Immunology* (2nd ed). Philadelphia: W. B. Saunders Co., pp222–235, 1994.